


# **ExamLearn.ie**



## **Musculoskeletal System**

# Musculoskeletal System

3.5 Responses to Stimuli	Objectives	G, O, R
3.5.3 Responses in the Human -- Musculoskeletal System	<ol style="list-style-type: none"> <li>1. Give 4 functions of the skeleton</li> <li>2. Name 4 parts of the body protected by the skeleton</li> <li>3. Name the structural division of the skeleton into two parts</li> <li>4. Use model of the human skeleton to identify the axial region and its main parts</li> <li>5. Use model of the human skeleton to identify the appendicular region and its main parts</li> <li>6. Name 4 component parts of the axial skeleton:</li> <li>7. Locate and give a function for: skull, vertebrae, ribs, and sternum</li> <li>8. Show the position and function of discs in relation to vertebrae.</li> <li>9. Show the position of these vertebrae: cervical (7), thoracic (12), lumbar (5), sacrum (5), and coccyx (4).</li> <li>10. Name the main component parts of the appendicular skeleton</li> <li>11. Show the position of the pectoral and pelvic girdles and their attached limbs.</li> <li>12. Name the two main parts of the Pectoral girdle</li> <li>13. Use a model of the human skeleton to identify the clavicle (collar bone) and scapula (shoulder blade).</li> <li>14. Name the appendages attached to the Pectoral girdle</li> <li>15. Use a model of the skeleton to identify the humerus, radius, ulna, carpal, metacarpals, digits (fingers) containing phalanges.</li> <li>16. Use a model of the skeleton to identify the Pelvic girdle</li> <li>17. Name the appendages attached to the Pelvic girdle</li> <li>18. Use a model of the skeleton to identify : femur, patella, tibia, fibula, tarsals, metatarsals, digits (toes) containing phalanges</li> <li>19. Draw a long bone to show its anatomy</li> <li>20. Name the cavity in the centre of the long bone</li> <li>21. Tell the visual difference between compact and spongy bone</li> <li>22. Give the composition of cartilage</li> <li>23. Give the function of cartilage on the tips of the long bone</li> <li>24. Give the composition of compact bone</li> </ol>	

	<p>25. Give the function of compact bone</p> <p>26. Give the composition of spongy bone</p> <p>27. Give the function of spongy bone</p> <p>28. Say what fill the spaces of spongy bone</p> <p>29. Give the function of red marrow</p> <p>30. Give the function of yellow marrow</p> <p>31. Visually identify the main parts of a long bone</p> <p>32. Show the mineral content in bone</p> <p>33. Show the organic component</p> <p>34. Say what would happen if a bone was put in acid</p> <p>35. Say what would happen if a bone was burned</p> <p>36. Say what a joint is</p> <p>37. Classify joints into different types</p> <p>38. Show the position of the various types of joint on a model skeleton</p> <p>39. Give the function of the different types of joint</p> <p>40. Say what an immovable joint is</p> <p>41. Give an example of an immovable joint</p> <p>42. Say what a slightly movable joint is</p> <p>43. Give an example of a slightly movable joint</p> <p>44. Say what a synovial joint is</p> <p>45. Describe the structure of one synovial joint.</p> <p>46. Give an example of a hinge joint</p> <p>47. Give an example of a ball &amp; socket joint</p> <p>48. Give the role of cartilage and ligaments in joints</p> <p>49. Give the role of tendons</p> <p>50. Explain the general relation of muscles to the skeleton</p> <p>51. Explain the term "antagonistic muscle pairs"</p> <p>52. Give an example of an antagonistic muscle pair</p> <p>53. Explain the need for muscles to be in pairs like this</p> <p>54. Use a model of the skeleton to highlight (a) the position and (b) the function of each type of joint.</p> <p>55. Can you name 2 disorder of the musculoskeletal system</p> <p>56. Explain what the symptoms of arthritis might be</p> <p>57. For arthritis, give 1 possible cause, a prevention, and a treatment.</p> <p>58. Explain what the symptoms of osteoporosis might be For osteoporosis, give 1 possible cause, a prevention, and a treatment.</p>	
3.5.8.H Bone Growth &	<p>59. Draw a long bone to show its anatomy</p> <p>60. Say what the skeleton of the embryo is first made of</p>	89.

Development	<p>61. Explain what an osteoblast is</p> <p>62. Explain what cartilage is</p> <p>63. Give the composition of cartilage</p> <p>64. Explain what a matrix is</p> <p>65. What materials bones are composed of</p> <p>66. Say where growth occurs in a bone</p> <p>67. Distinguish between the head and shaft of a bone</p> <p>68. Explain what happens at a growth plate</p> <p>69. Say when a skeleton will have reached its adult height</p> <p>70. Give the function of cartilage on the tips of the long bone</p> <p>71. Give the composition of compact bone</p> <p>72. Give the function of compact bone</p> <p>73. Explain why bone is called a composite material</p> <p>74. Give the composition of spongy bone</p> <p>75. Give the function of spongy bone</p> <p>76. Say what fill the spaces of spongy bone</p> <p>77. Give the function of red marrow</p> <p>78. Give the function of yellow marrow</p> <p>79. Explain why a bone crumbles if you burn it</p> <p>80. Explain why a bone becomes flexible bendy if you put it in acid for a day</p> <p>81. Visually identify the main parts of a long bone</p> <p>82. Distinguish between osteoclasts and osteoblasts</p> <p>83. Explain why most of your bones are less than 10 years old.</p> <p>84. Give 2 functions of osteoclasts</p> <p>85. Say which mineral in our diet is stored in our bones</p> <p>86. Give three functions of Calcium in the body</p> <p>87. Name 3 factors that influence the continued renewal of bone in the skeleton</p> <p><b>88. Name two things you can do in your everyday life to help to build up strong bones and teeth</b></p>	
-------------	---------------------------------------------------------------------------------------------------------------------------------------------------------------------------------------------------------------------------------------------------------------------------------------------------------------------------------------------------------------------------------------------------------------------------------------------------------------------------------------------------------------------------------------------------------------------------------------------------------------------------------------------------------------------------------------------------------------------------------------------------------------------------------------------------------------------------------------------------------------------------------------------------------------------------------------------------------------------------------------------------------------------------------------------------------------------------------------------------------------------------------------------------------------------------------------------------------------------------------------------------------------------------------------------------------------------------------------------------------------------------------------------------------------------------------------------------------------------------------------------------------------------------------------------------------------------------------------------------------------------------------	--

There are two types of skeleton:

- **Exoskeleton** e.g. insects.
- **Endoskeleton** e.g. humans

Skeleton is made up of **bone** and **cartilage** , with muscle attached to the outside.

Bones are held together by **ligaments** and move due to the forces produced by muscles which are attached to the bones by **tendons**.

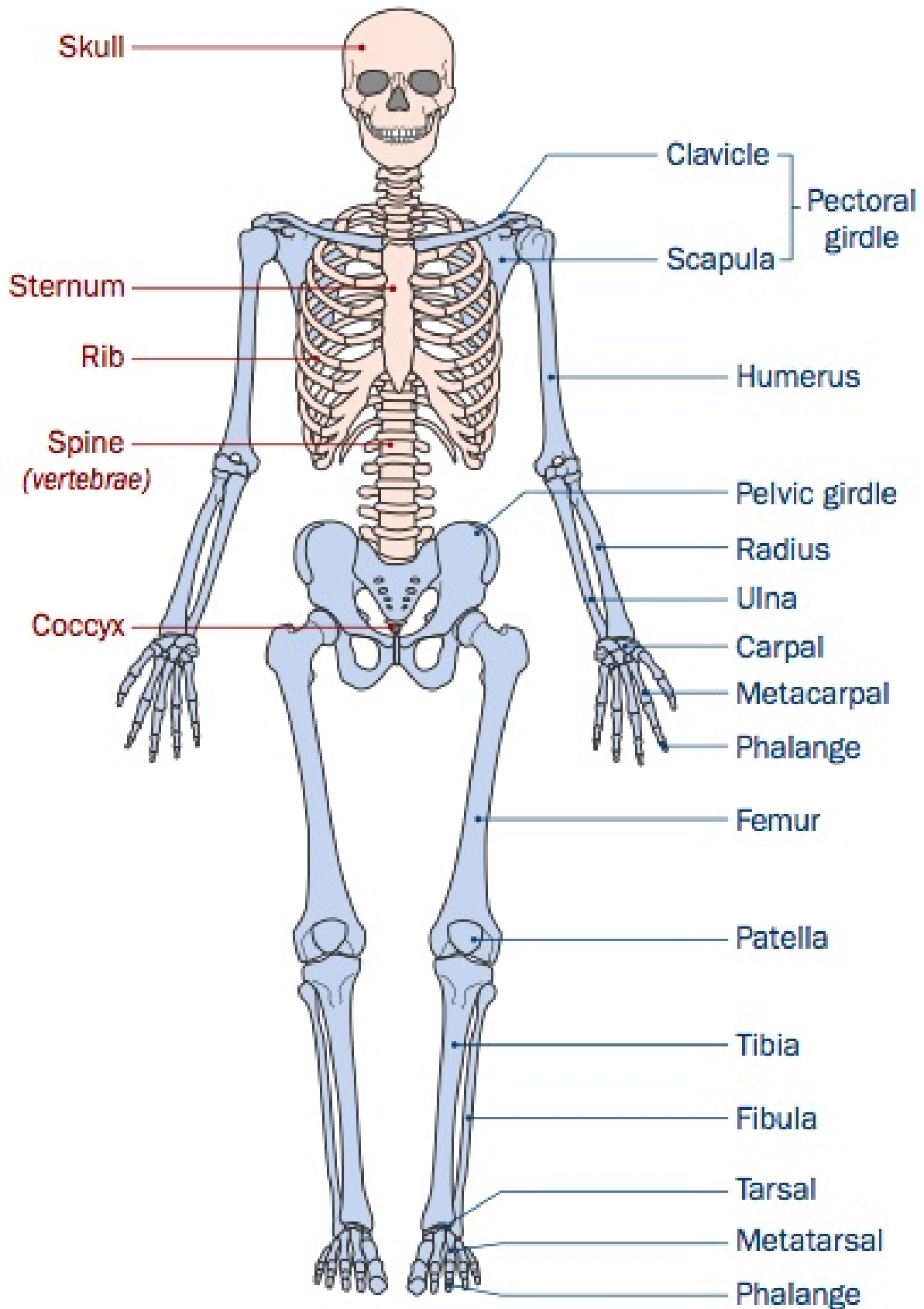
## Functions of human skeleton:

- **Support & Shape**
- **Protection** - of internal organs e.g. vertebral column protects spinal cord, skull protects brain, rib cage protects heart & lungs,
- **Movement** - bone gives muscles a base against which to pull.
- **Blood cell production** - by bone marrow.
- Breathing (with the help of intercostal muscles)

- Transmission of sound waves in middle ear.
- Storage of calcium & phosphorus

## THE AXIAL SKELETON

## THE APPENDICULAR SKELETON



The skeleton is divided into two parts: the axial skeleton and the appendicular skeleton.

# Axial Skeleton

## 1. Skull (Cranium)

Made up of 22 fused bones. Sutures = immovable joints in the skull.

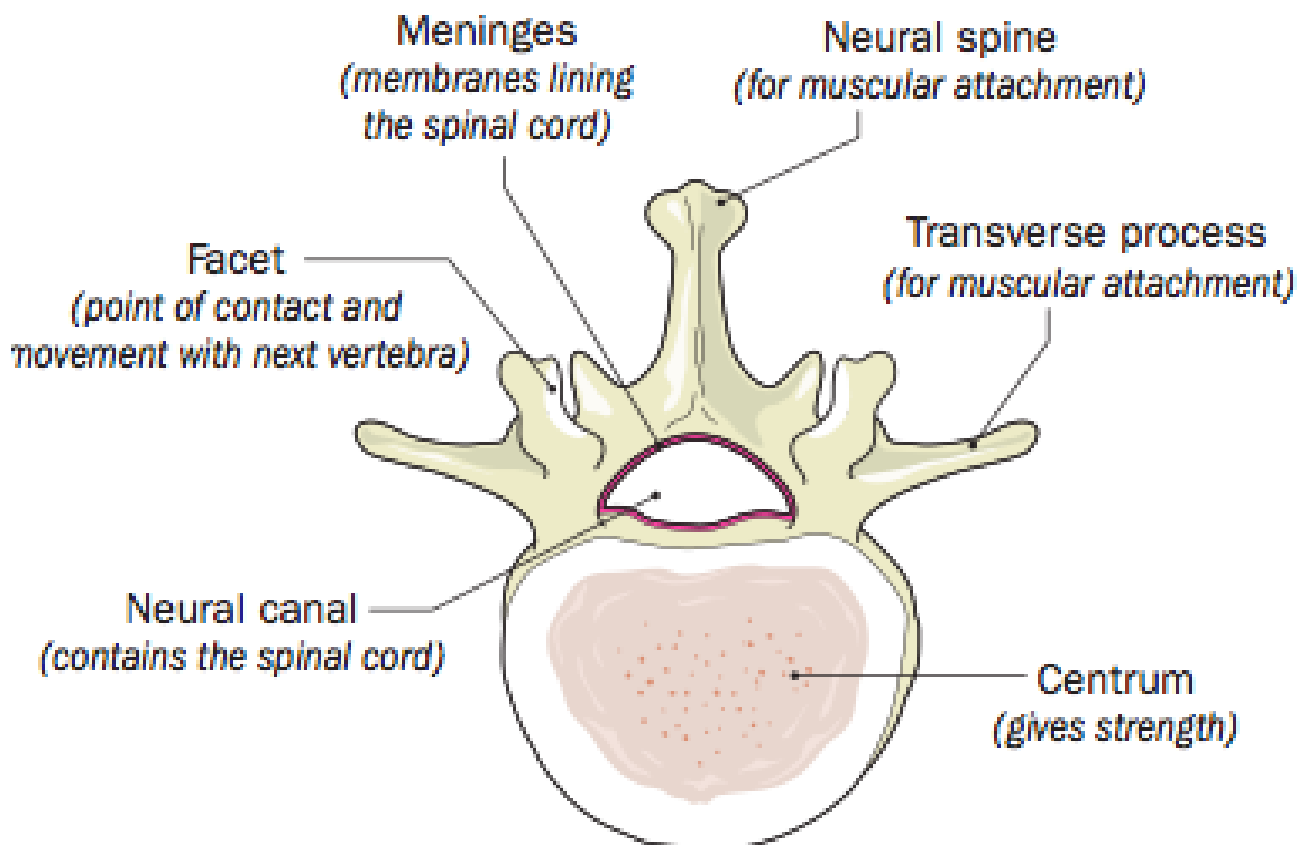
- Protects the brain.
- Contains sense organs - eyes, ears & nose.
- Has fixed upper jaw & movable lower jaw.

## 2. Vertebral Column (Backbone)

Made up of 33 vertebrae

- **Cervical (7)** - (neck)
- **Thoracic (12)** (chest)
- **Lumbar (5)** (back)
- **Sacral (5 fused) \*\* \*\*** (hip)
- **Coccyx (4 fused)** (tail)

Vertebra:



Discs made of cartilage lie between the vertebrae

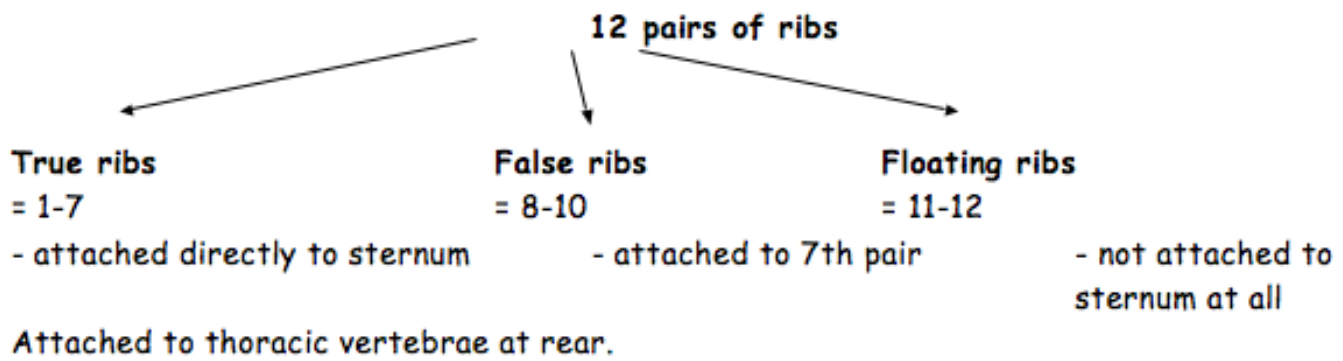
- this allows for movement between the vertebrae
- discs act as shock-absorbers.

'**Slipped disc**' - occurs when the outer fibrous coat of the cartilage disc becomes torn or damaged. It then bursts and the soft elastic muscle in the centre pushes onto nerves, causing pain in the spine.

## 3. Sternum & Ribs

- protect lungs
- help in breathing





## Appendicular Skeleton

1. **Pentadactyl Limbs - arms and legs**
2. **Girdles**

### **Pectoral (shoulder) Girdle**

- Consists of collarbone (clavicle) and shoulder blade (scapula). It forms a connection with vertebral column and arms.

### **Pelvic (hip) Girdle**

Consists of the hip bones, sacrum and legs.

- helps support weight of body
- allows articulation with the leg muscles

## Bones

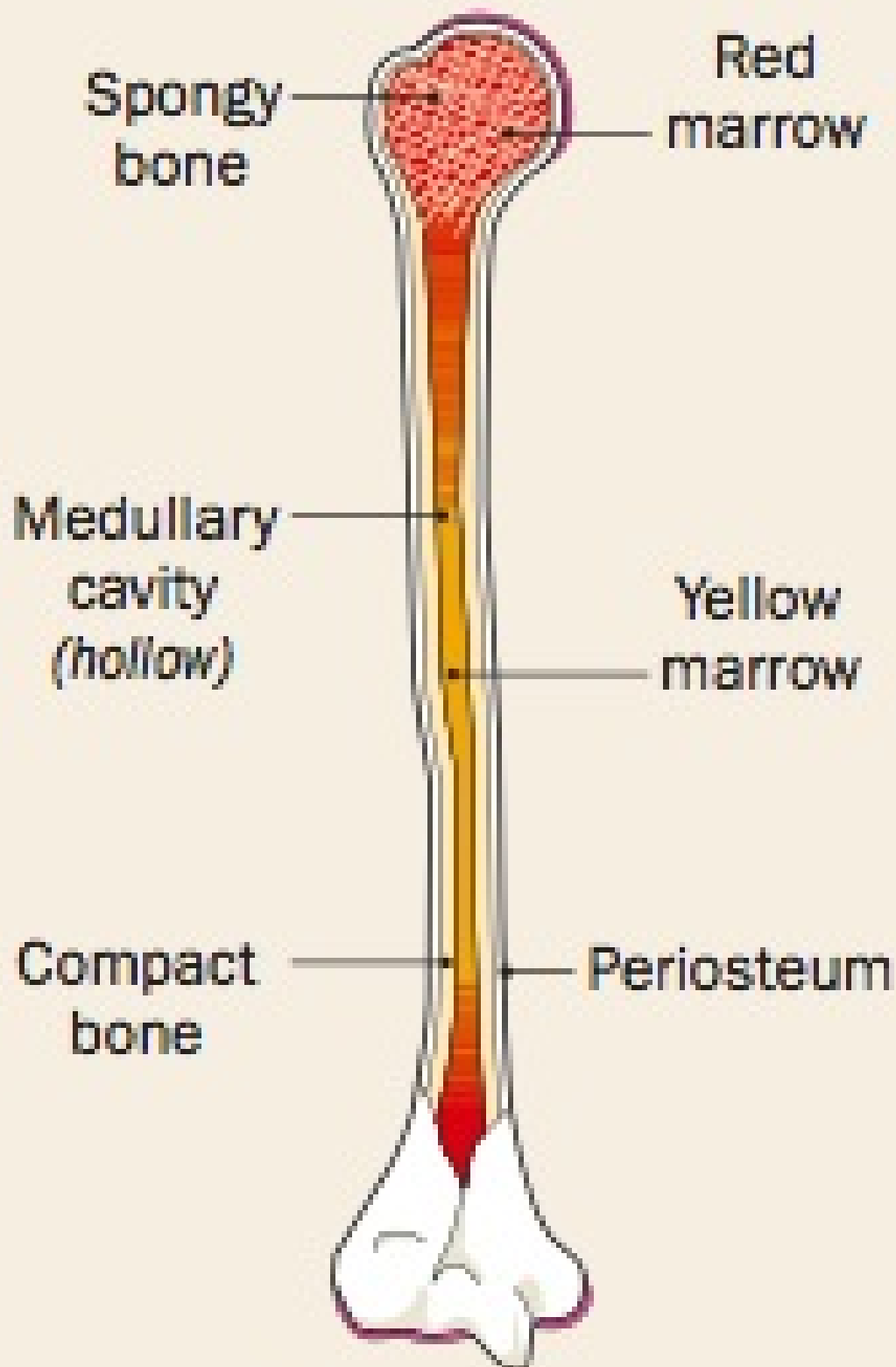
- Human adult has 206 bones.
- Newborn baby has 350 bones.
- Bone makes up 8 % of body mass.
- Three types of bone: flat bone (skull), long bone (limb), short bones (wrist and ankles)

## Cartilage

Contains a flexible fibrous protein - collagen. Collagen fibres are embedded in a matrix (surrounding material) of calcium and phosphorus salts. It is lacking in blood vessels and nerves. It depends on materials diffusing through to the cells that form it. Why cartilage is slower to heal than bone!

It covers the tips of bones where they meet in joints and so reduces friction. It also acts as a shock absorber. Also found in pinna of ear, nose, trachea and between vertebrae.

### **L.S. of a long bone (external and internal structure)**



**LS of long bone**

Bones are designed to give maximum strength with minimum weight. Bones are made up of layers.

- **Periosteum** - fibrous coat
- **Compact bone** - made of bone cells (osteoblasts) embedded in a matrix (=70% inorganic (non-living) salts and 30% protein (collagen). Calcium salts e.g. calcium phosphate, give bone its strength while protein gives bone its flexibility. Found mostly in shaft (diaphysis) of a bone and as a layer around the ends of bones.
- **Spongy bone** - like compact bone that contains numerous hollows ('Aero') to minimise weight. Spaces are filled with red bone marrow that produces blood cells.



- **Hollow centre (medullary cavity)** - contains inactive yellow bone marrow. Stores fat. This bone marrow can convert to red bone marrow if the body requires increase blood cell formation.

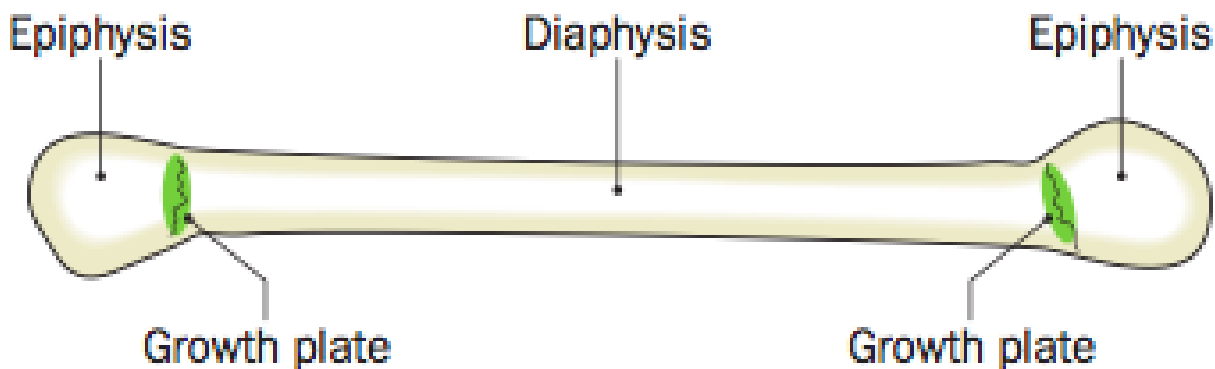
### Expt.: To investigate the composition of bone

- (1) Bone in water (control) - strong, hard, rigid (doesn't bend)
- (2) Bone in acid - soft & flexible (Calcium salts dissolve in acid)
- (3) Bone heated - black & brittle (organic matter burns away - mass dec.)

## Bone growth

Embryonic cartilage begins to be replaced with bone around the **eighth** week of development in the uterus. **Osteoblasts** are bone cells responsible for ossification - conversion of cartilage into bone. They produce collagen and then a hard compound, usually calcium phosphate forms around the collagen fibres. The osteoblasts become trapped in this hard compound and become dormant bone cells.

The increase in length of a bone is due to a growth plate found between the epiphysis and the diaphysis. In this plate cartilage is continually formed and turned into bone. The growth plate ceases to function at adulthood. People in need of growth must receive injections before the cartilage discs have disappeared.



## Bone development

Bone is continually being broken down and built up again (10times!). Bone-digesting cells in the medullary cavity digest the bone that lines the cavity and release calcium in to the blood. The osteoblasts make new bone.

**Renewal of bone** - depends on physical activity, hormones and diet.

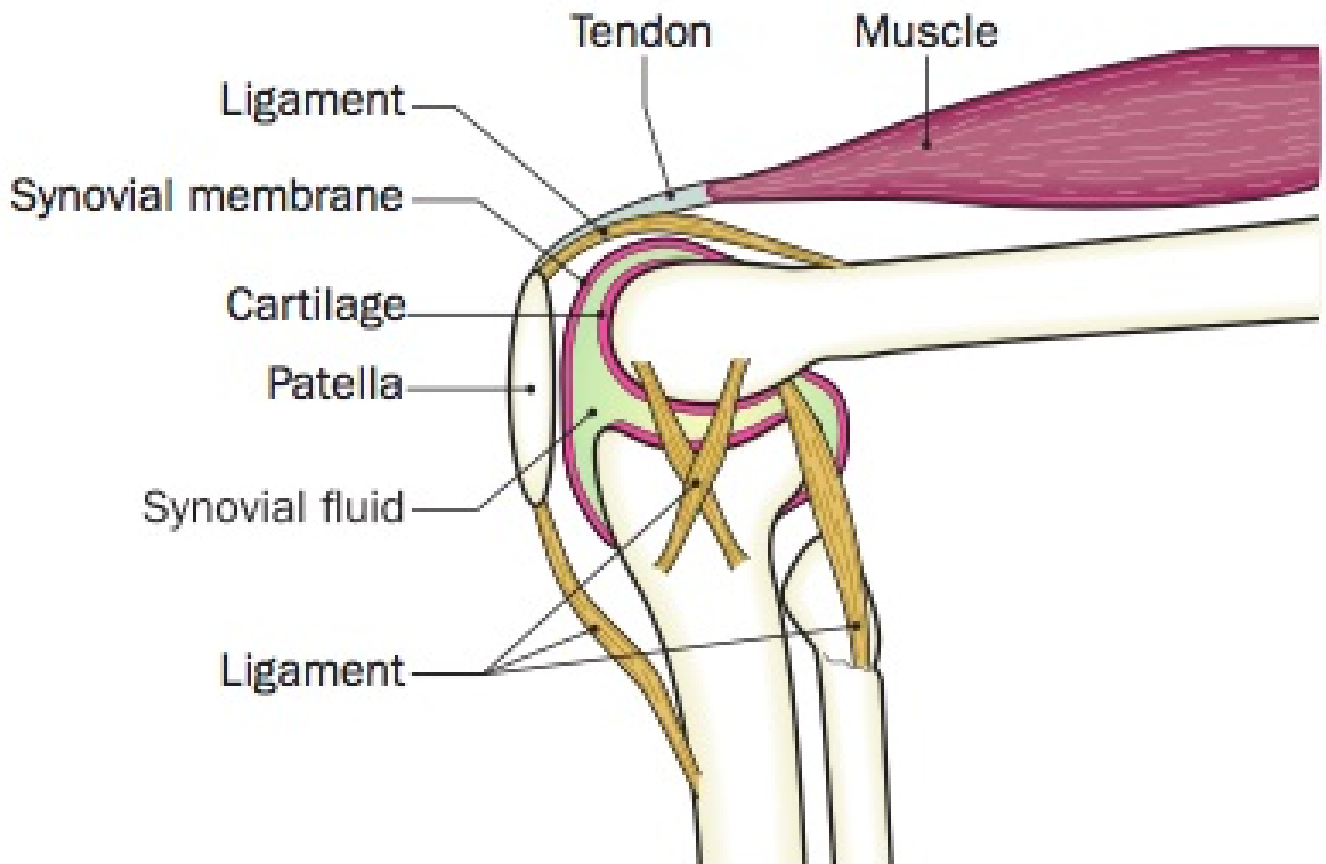
- When bones are stressed by physical activity they become thicker and stronger (osteoblasts are stimulated).
- Growth hormones and many sex hormones increase the size of bones. Seen at puberty y when bone mass may increase rapidly. Parathormone removes calcium from bone so that blood calcium levels can be raised - essential for muscles and nerves to work properly.
- Sufficient supply of calcium is needed in the diet.

## Joints

A joint is formed where 2 or more bones meet.

- **Immovable** (fused) – bones are in contact e.g. skull, pelvis
- **Slightly movable** e.g. spinal column
- **Movable** e.g. ball and socket (movement in most directions but weak e.g. hip) and hinge (movement in one direction but very strong e.g. knee)

## Synovial joint - knee



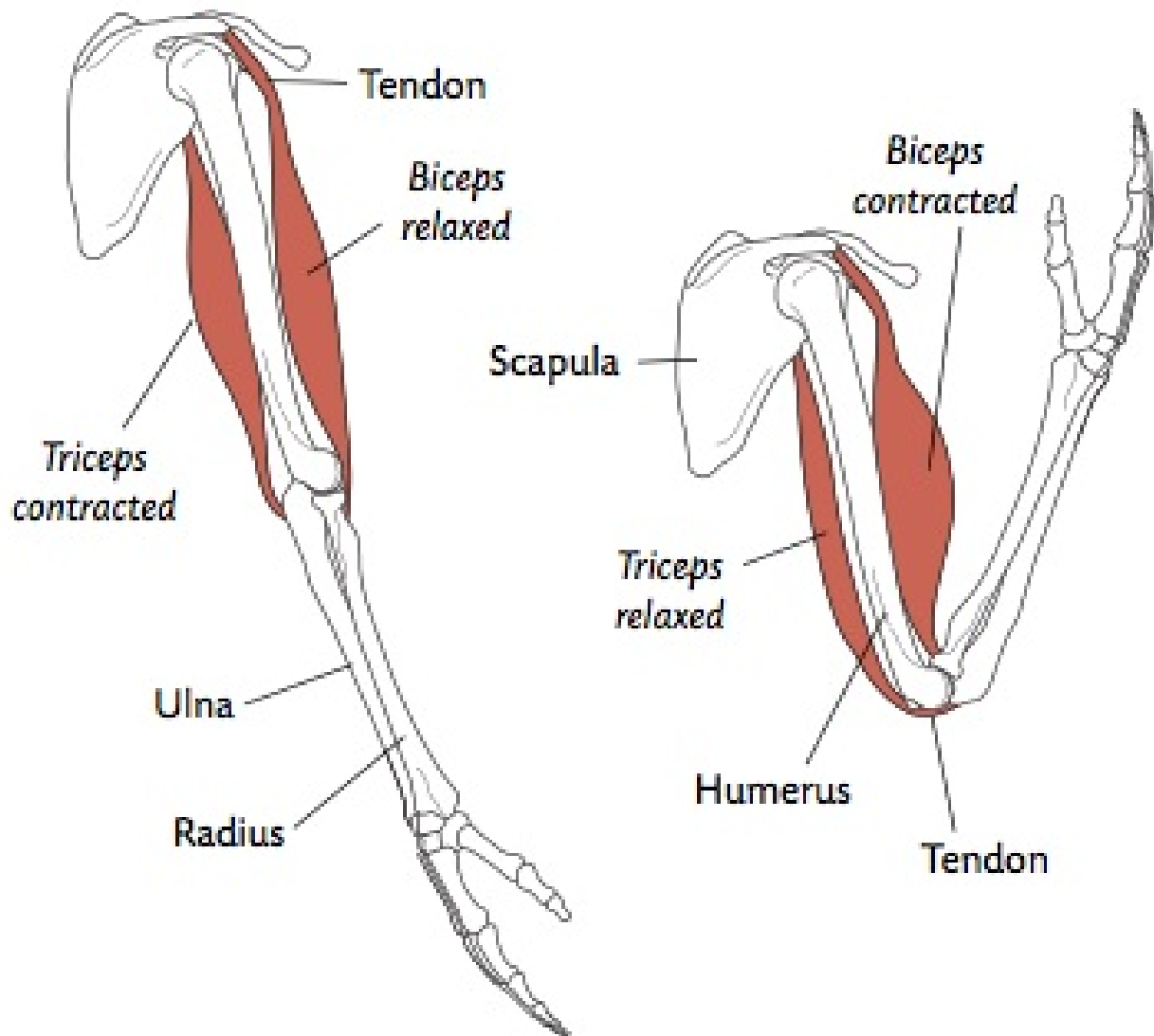
- Bones are covered by a layer of cartilage & are held together by a **capsule of ligaments**. These ligaments are elastic enough to allow the required range of movement.
- The **cartilage** acts as a shock absorber & allows free, smooth movement between the bones.
- **Synovial membrane** secretes synovial fluid into the joint.
- **Synovial fluid** lubricates & reduces friction. It also provides nourishment for living cartilage.

## Muscles

- **Skeletal muscle** – concerned with body movements – can contract quickly but tires very easily (try fist open/close for 1 min). Under voluntary control.
- **Smooth muscle** – found in internal structures e.g. digestive system, blood vessel, bladder and uterus. It contracts slowly and is slow to tire. Under involuntary or unconscious control.
- **Cardiac muscle** – heart. It is involuntary. It has many mitochondria, contracts strongly and does not tire as easily as skeletal muscle.

**Antagonistic muscles** are pairs of muscles working as "opposites" to control movement e.g. biceps & triceps.

- Bending arm (flexion) - the biceps ( **flexors** ) contract & triceps relax.
- Straightening arm (extension) - the triceps ( **extensors** ) contract & biceps relax.
- When the muscle contracts it shortens & fattens, the tendon pulls on the bone causing it to move.



Musculoskeletal disorder – *study either osteoporosis or arthritis.*

- **Arthritis** - joint inflammation
- **Osteoarthritis** - cartilage on the tips of bones wears away as the person ages. The underlying bones enlarge and more synovial fluid forms.
- **Prevention** - Try reducing damage to joints e.g. use proper footwear when running, avoid running on hard surfaces (try walking, swimming instead).
- **Treatment** - No cure. Treatments include rest, exercise to maintain mobility and strength, weight loss, anti-inflammatory medications and possibly surgery to replace joint.

**Rheumatoid arthritis** - the immune system attacks the joint and causes pain and inflammation. Synovial membranes are attacked first. The joint swells and in time may become damaged and deformed.

- **Cause** - maybe a bacterium or viral infection or family history.
- **Treatment** - joints can be replaced by artificial joints e.g. hip replacements.

## Osteoporosis

Osteoporosis is the loss of protein (collagen) material from bone. It causes it to become brittle and easily broken.

- **Cause** -bone replacement has slowed down and is now slower than the normal rate of bone breakdown. More common in women, especially after menopause when levels of oestrogen fall.
- **Prevention** - Physical exercise during puberty will increase density by almost 20 per cent, particularly for females.
- **Treatment** - Hormone replacement therapy (HRT) for menopausal females as the oestrogen hormone reduces bone loss, but the bone material already lost is not replaced. Physical exercise and a diet rich in calcium and vitamin D are also recommended.

## Rickets

**Cause** - lack of calcium or vitamin D. Bone grows but is not hardened with the calcium salts. The weight of the body, along with movement, puts a strain on the softer bone, which bends and distorts.

- NB: Osteomalacia (adult form of rickets) is the loss of minerals (calcium) from bone due to lack of vitamin D